



## FAU Institutional Repository

<http://purl.fcla.edu/fau/fauir>

This paper was submitted by the faculty of [FAU's Harbor Branch Oceanographic Institute](#).

Notice: ©2002 JWD Online by Wildlife Disease Association. This manuscript is available at [www.jwildlifedis.org/](http://www.jwildlifedis.org/) and may be cited as: Ewing, R., Zaias, J., Stamper, M. A., Bossart, G. D., & Dubey, J. P. (2002). Prevalence of Sarcocystis sp. in stranded Atlantic white-sided dolphins (*Lagenorhynchus acutus*). *Journal of Wildlife Diseases*, 38(2), 291-296.

## PREVALENCE OF *SARCOCYSTIS* SP. IN STRANDED ATLANTIC WHITE-SIDED DOLPHINS (*LAGENORHYNCHUS ACUTUS*)

Ruth Ewing,<sup>1,2,8</sup> Julia Zaias,<sup>1</sup> M. Andrew Stamper,<sup>3,4</sup> Gregory D. Bossart,<sup>5,6</sup> and J. P. Dubey<sup>7</sup>

<sup>1</sup> University of Miami School of Medicine, Department of Pathology, Division of Comparative Pathology, 1600 NW 10th Avenue, Room 7101A, Miami, Florida 33136, USA

<sup>2</sup> NOAA, National Marine Fisheries Service, Southeast Fisheries Science Center, Miami, Florida 33149, USA

<sup>3</sup> New England Aquarium, Central Wharf, Boston, Massachusetts 02110, USA

<sup>4</sup> Current address: EPCOT, The Living Seas, EC TRL W-251, P.O. Box 10,000 Lake Buena Vista, Florida 32830, USA

<sup>5</sup> Miami Seaquarium, 4400 Rickenbacker CSWY, Miami, Florida 33149, USA

<sup>6</sup> Current address: Harbor Branch Oceanographic Institute, Division of Marine Mammal Research and Conservation, 5600 US 1 North, Fort Pierce, Florida 34946, USA

<sup>7</sup> USDA, Agricultural Research Service, Parasite Biology, Epidemiology and Systematics Laboratory, BARC-East, Beltsville, Maryland 20705, USA

<sup>8</sup> Corresponding author: (e-mail: Ruth.Ewing@noaa.gov)

**ABSTRACT:** In January 1998 and 1999, two mass strandings of dolphins occurred in Wellfleet, Massachusetts. The strandings were composed of 97 and 53 animals, respectively. Tissues from 35 Atlantic white-sided dolphins (*Lagenorhynchus acutus*) from the 1998 stranding and 52 from the 1999 stranding were examined histologically. In the 1998 stranding, unidentified protozoal tissue cysts were seen in skeletal muscle from 11 of 28 (39%) dolphins. In addition, two dolphins had a protozoal tissue cyst in cardiac muscle. In the 1999 stranding, nine of 23 (39%) dolphins had the same protozoal tissue cysts in skeletal muscle. The identification of these protozoal tissue cysts as *Sarcocystis* sp. was confirmed by light and transmission electron microscopy. The high prevalence of sarcocysts in these dolphins suggests that they are likely intermediate hosts for previously undescribed *Sarcocystis* spp. The ultrastructure of the sarcocyst walls suggests that more than one species of *Sarcocystis* are present in dolphins.

**Key words:** Atlantic white-sided dolphin, epidemiology, *Lagenorhynchus acutus*, protozoan, *Sarcocystis*.

### INTRODUCTION

*Sarcocystis* spp. (Protozoa: Apicomplexa) have an obligatory two-host (predator-prey) life cycle (Dubey et al., 1989). The intermediate host, typically an herbivore, becomes infected by ingesting feces or water which contains infective sporocysts. After ingestion, the parasite undergoes asexual multiplication in several organs and eventually forms sarcocysts in muscles. Sarcocysts contain banana-shaped bradyzoites. When the intermediate host is consumed by a carnivorous definitive host, bradyzoites are released from the sarcocyst and penetrate the lamina propria of the small intestine. Here they transform into gamonts. After fertilization, oocysts containing sporocysts are released into the intestinal lumen and passed out in feces (Dubey et al., 1989).

Sarcocysts have been identified in many wild and domestic terrestrial mammals (Dubey et al., 1998); however, few have

been documented in marine mammals. Several studies have identified sarcocysts in individual pinnipeds (Lapointe et al., 1998) and cetaceans (DeGuise et al., 1993). This study documents a relatively high prevalence of sarcocysts in Atlantic white-sided dolphins (*Lagenorhynchus acutus*) associated with two mass strandings.

### METHODS

In January, 1998 and 1999, members of the Northeast Regional Stranding Network responded to two mass strandings of dolphins in Wellfleet, Massachusetts (41°56'N, 70°02'W). These strandings involved two cetacean species, 90 Atlantic white-sided dolphins and 17 common dolphins (*Delphinus delphis*). Only Atlantic white-sided dolphins were evaluated by light microscopy. The University of Miami Comparative Pathology Laboratory received tissues from 35 Atlantic white-sided dolphins from the 1998 stranding (15 males and 20 females) and 50 from the 1999 stranding (31 males, 17 females, and two unknown sexes) for

histologic evaluation. Lengths of males and females were similar in 1998 and 1999 so data were pooled for analyses. The average body length was  $210 \pm 31$  cm and  $212 \pm 32$  cm in 1998 and 1999, respectively. Mean male body length was  $221 \pm 32$  cm and mean female body length was  $198 \pm 26$  cm for both years combined. Findings in skeletal and cardiac muscle are reported here.

Representative skeletal muscle was not submitted for every animal, nor was muscle location indicated for each specimen received in 1998. Skeletal muscle samples from dolphins in the 1999 stranding were obtained from the left lateral epaxial muscles. All samples were submitted in neutral buffered 10% formalin. After processing, the muscle was embedded in paraffin, sectioned at  $5 \mu\text{m}$ , and stained with hematoxylin and eosin (HE) for routine histopathology. Several samples with sarcocysts were processed for transmission electron microscopy (TEM). Tissue blocks were deparaffinized in 100% xylene then infiltrated and polymerized in Spurr's Resin. Tissues were then thick ( $0.5\text{--}1.0 \mu\text{m}$ ) and thin ( $70\text{--}80$  nm) sectioned on a Sorvall Porter-Blum MT2 ultramicrotome. Thin sections were stained in 50% methanolic uranyl acetate and lead citrate and then viewed and photographed on a JEOL CX-100 transmission electron microscope.

## RESULTS

Mild skeletal muscle fiber degeneration and mild multifocal infiltrates of lymphocytes and plasma cells characterized skeletal muscle samples. The presence of sarcocysts within muscle bundles was a striking finding in 11 of 28 (39%) and nine of 23 (39%) dolphins in 1998 and 1999, respectively. The location of the skeletal muscle tissue containing sarcocysts was known only for a few animals; these sites included subcutaneous skeletal muscle and diaphragm. None of the sarcocysts were associated with inflammation.

Cardiac muscle also had mild diffuse degenerative changes. Two of 31 (6%) animals from the 1998 stranding had a sarcocyst in cardiac muscle; none were seen in dolphins from the 1999 stranding. Inflammation was not associated with these sarcocysts.

Thirty-six sarcocysts were measured from 15 skeletal and one cardiac muscle sections. The sarcocysts were round to oval

and  $115.8 \pm 75 \mu\text{m}$  (mean  $\pm$  SD) in diameter and were located within myocytes. In  $5\text{-}\mu\text{m}$  thick sections stained with H&E, the sarcocyst wall appeared  $<2 \mu\text{m}$  thick with barely visible undulations or protrusions. In  $1\text{-}\mu\text{m}$  sections stained with toluidine blue, additional details of the sarcocyst wall were visible. The sarcocysts from dolphin No. 1 had a  $<1 \mu\text{m}$  thick sarcocyst wall without recognizable villar protrusions (Fig. 1A). The walls from the sarcocysts in dolphins Nos. 2 and 3 were  $1\text{--}2 \mu\text{m}$  thick and had small conical villar protrusions (Fig. 1B, C). Bradyzoites were approximately  $5 \mu\text{m}$  long in all three sarcocysts.

The ultrastructural appearance of the three sarcocysts in Figure 1 is shown in Figure 2. In all three sarcocysts, the parasitophorous vacuolar membrane was lined by an electron-dense layer (El). The El was interrupted at irregular distances (Fig. 2). The villar protrusions (VP) on sarcocyst walls differed in structure. The sarcocyst wall (Cw) in Figure 2A from dolphin No. 1 appears smooth without any appreciable villar protrusions. In the sarcocyst from dolphin No. 2, the VP had a conical shape (Fig. 2B).

In the sarcocyst in dolphin No. 3, the VP were most prominent with a wide base and a rounded villar tip (Fig. 2C). The ground substance in all sarcocysts was smooth without microtubules or prominent granules.

Voucher histologic sections of muscles from the dolphins were deposited in the U.S. National Parasite Collection, Beltsville, Maryland as USNPC Nos. 91695(dolphin 1), 91696(dolphin 2), 91697(dolphin 3).

## DISCUSSION

This report is the first to demonstrate a relatively high prevalence of sarcocysts in stranded Atlantic white-sided dolphins. Sarcocysts were previously described, although not identified, in a single Atlantic white-sided dolphin (DeGuise et al., 1993).

Identification of sarcocysts by light mi-

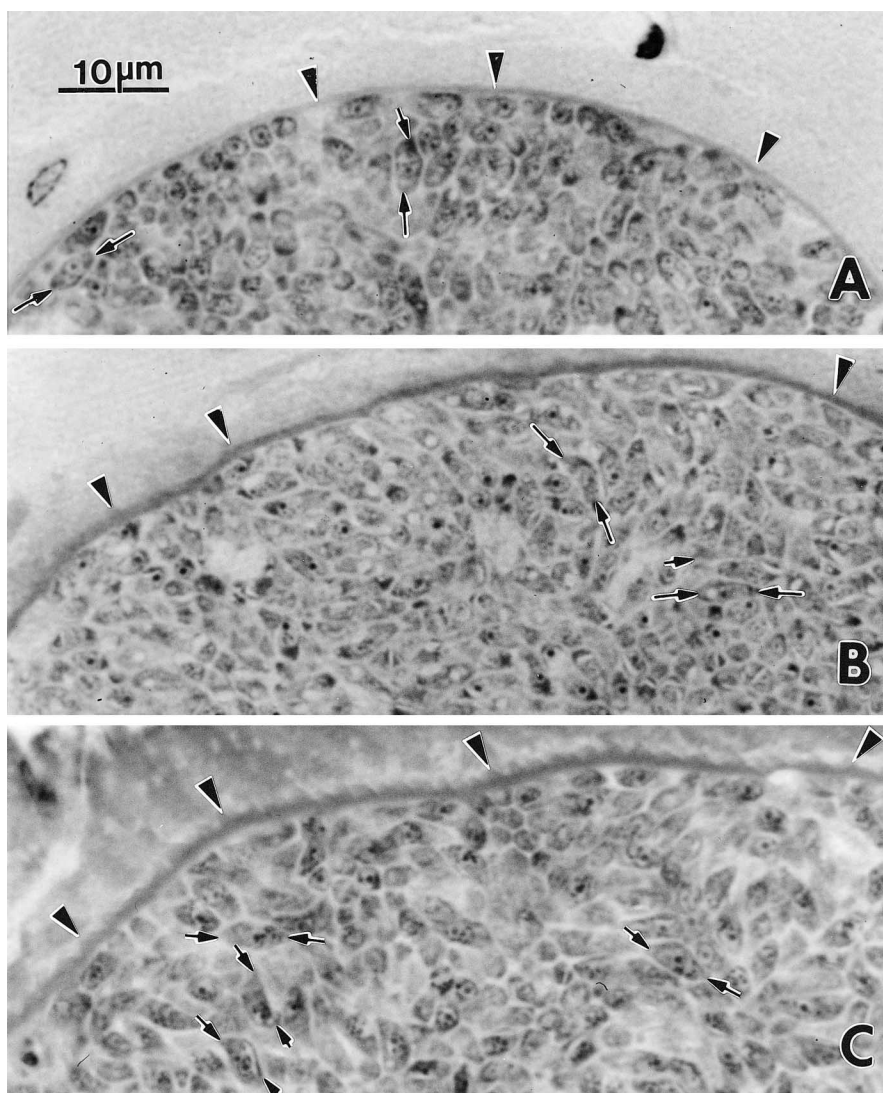


FIGURE 1. Sarcocysts of *Sarcocystis* spp. in tissue sections of muscles of three dolphins. Note differences in the thickness and character of the sarcocyst wall (arrowheads). Opposing arrows point to longitudinally-cut bradyzoites. A. Dolphin No. 1. Note thin sarcocyst wall without any visible villar protrusions. B. Dolphin No. 2. Note small villar protrusions on the sarcocyst wall. C. Dolphin No. 3. Note small, deciduous teeth-like protrusions (arrows) on the sarcocyst wall. 1- $\mu$ m sections stained with toluidine blue. Bar = 10  $\mu$ m applies in all figures.

scopy is difficult due to variation in sarcocyst size and shape as a result of contractile state of the muscle, age of sarcocyst, type of host cell parasitized, and method of fixation (Dubey et al., 1989). Similarly, metrocyte and bradyzoite size and shape can be highly variable depending on stage of division and how tightly they are packed into the cyst. Ultrastruc-

tural characteristics of the sarcocyst wall provide more reliable criteria for identification (Dubey et al., 1989).

Recent reports have documented encephalitis in sea otter (*Enhydra lutris*; Rosonke et al., 1999, Lindsay et al., 2000) and Pacific harbor seal (*Phoca vitulina richardsi*; LaPointe et al., 1998) associated with *S. neurona*-like schizonts. However,

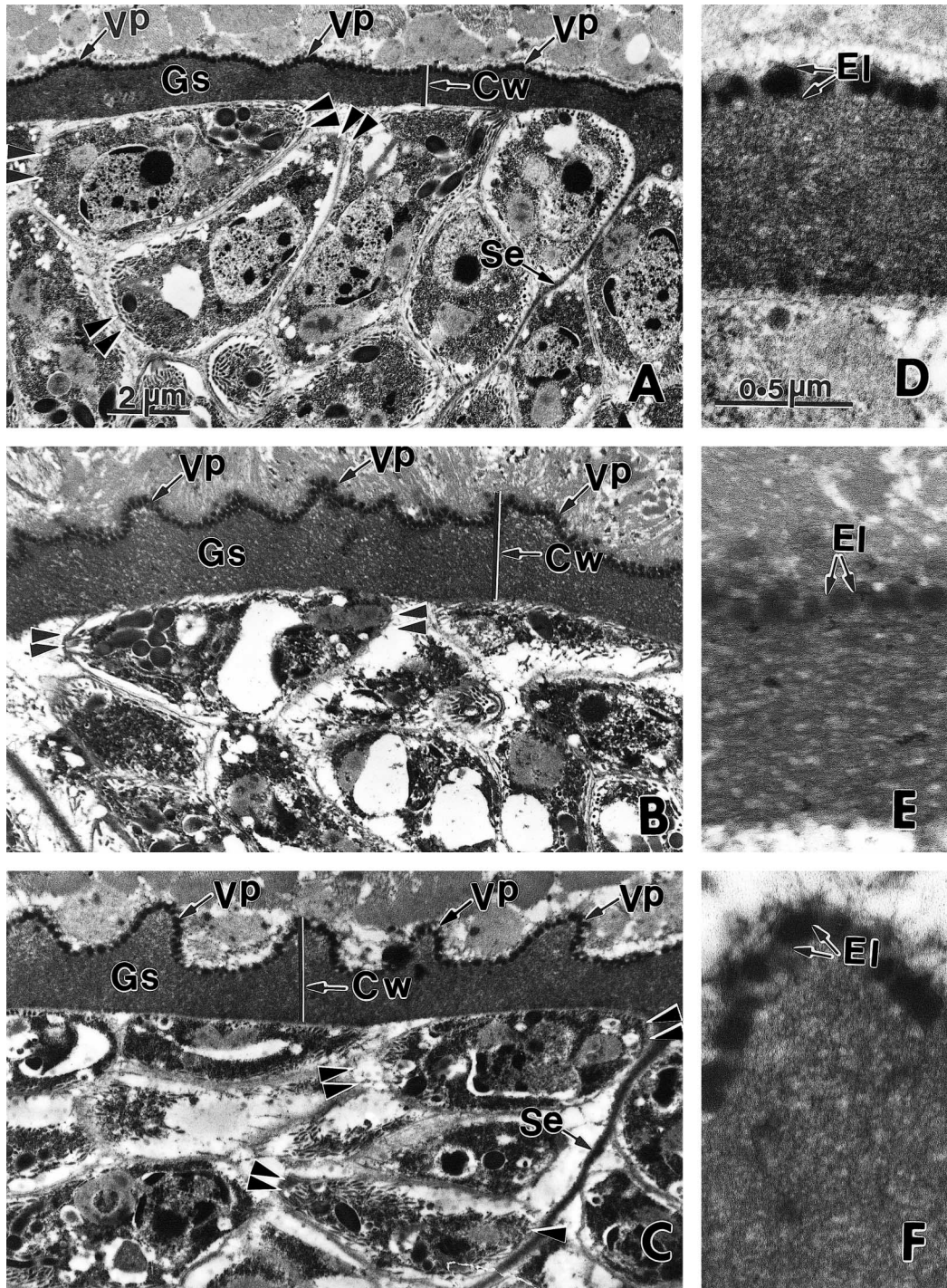


FIGURE 2. Transmission electron micrographs of sarcocysts from the three dolphins shown in Figure 1, respectively. Figures on the left (A–C) are low power of the sarcocysts and figures on the right (D–F) are high power of the sarcocyst wall (Cw). Note differences in heights of villar protrusions (VP), ground substance (Gs), and structures of bradyzoites. Opposing arrows point to longitudinally-cut bradyzoites. Also note prominent septa (Se) and electron-dense layer (EI) lining the parasitophorous vacuolar membrane. A. Villar protrusions are very short. B. Villar protrusions are conical in shape. C. Villar protrusions are prominent. Uranyl acetate and lead citrate stain. Bar = 2  $\mu\text{m}$  A–C, bar = 0.5  $\mu\text{m}$  D–F.

sarcocysts of *S. neurona* were not described. Sarcocysts have been found in skeletal muscles of sea otters but their structure has not been characterized (Ronske et al., 1999, Lindsay et al., 2000). Sarcocysts in the present report are structurally distinct from sarcocysts of *S. neurona* (Dubey et al., 2000, 2001). Sarcocysts of *S. neurona* have elongated villar protrusions whereas sarcocysts in the present study had none or short villar protrusions.

Akao (1970) first reported sarcocysts in a whale (*Balaenoptera borealis*) that had been frozen. The sarcocysts were macroscopic, up to 20 cm long. The sarcocyst wall was 2–3  $\mu\text{m}$  thick and organisms within sarcocysts were 5–13  $\mu\text{m}$  long. Sarcocysts have also been reported in other species of whales (Cowen, 1966; Owen and Kakulus, 1967; Muday et al., 1978). Mehlhorn et al. (1976) illustrated wall of a sarcocyst from a sperm whale. The sarcocyst wall was structurally similar to the Type 1 sarcocyst wall found in *S. muris* in mice.

DeGuise et al. (1993) reported sarcocysts in section of muscle from two beluga whales (*Delphinapterus leucas*) and an Atlantic white-sided dolphin. The sarcocysts from beluga whales had thin sarcocyst walls but the thickness was not stated. Judging from the bar scale in the illustration they provided the sarcocyst wall was less than 0.2  $\mu\text{m}$  thick without any visible villar protrusions. No other details of the sarcocyst wall were given. The sarcocyst wall was considered to be structurally similar to sarcocysts in beluga whales although the details were not clear because the muscles had been frozen (DeGuise et al., 1993).

It was difficult to compare structure of the sarcocysts in the present study to those reported previously because not all details were available. The sarcocyst in dolphin No. 1 of the present study has the closest resemblance to sarcocysts from the beluga whale. Dubey et al. (1989) and Dubey and Odening (2001) classified types of sarcocyst walls. The structure of sarcocysts in the present study does not fit into any of

the described types. The sarcocyst in dolphin No. 1 has closest resemblance to Type 1 sarcocyst, but in Type 1 sarcocysts the sarcocyst wall has invaginations that were missing in the dolphin sarcocyst. The closest resemblance of the sarcocysts in dolphins No. 2 and 3 is to Type 9 sarcocysts of Dubey et al. (1989). However, Type 9 sarcocysts have prominent microtubules in villar protrusions that were absent in the present study. It was not possible to determine the prevalence of each type of sarcocyst because only a few sarcocysts were present. The total thickness of the sarcocyst wall (villar protrusions plus ground substance) is approximately 2  $\mu\text{m}$  in sarcocysts in dolphins No. 2 and 3. The measurements of villar protrusions are not given because villi were cut at different angles.

In summary, the sarcocysts in the Atlantic white-sided dolphins probably belong to different species but they are unnamed until well-preserved specimens have been studied. The sarcocysts in the two groups of dolphins were an incidental finding. The life cycle of *Sarcocystis* spp. in marine mammals is unknown. The high prevalence of sarcocysts in dolphins suggests that they are probably intermediate hosts for this parasite. Moreover, prevalence of this parasite in marine mammal and aquatic ecosystems is higher than previously described.

#### ACKNOWLEDGMENTS

We acknowledge members of the New England Aquarium's Rescue and Rehabilitation Program and the Northeast Regional Stranding Network for their efforts in processing the stranded animals. Marine mammal salvaged samples were collected, analyzed, and archived in accordance with National Marine Fisheries Service permits to the Marine Mammal Health and Stranding Response Program (No. 932-1489-01/PRT009526). Opinions or assertions presented are private views of the authors and are not to be construed as the official positions of the Department of Commerce or the Department of Agriculture. A. Fort, S. Decker, and B. Roberts were essential in processing of tissues for light and electron microscopy. This work was partially funded by the DHHS, Na-

tional Institutes of Health, National Center for Research Resources, grant T32 RR07057 (to JZ).

#### LITERATURE CITED

- AKAO, S. 1970. A new species of *Sarcocystis* parasitic in the whale *Balaenoptera borealis*. *Journal of Protozoology* 17: 290–294.
- DEGUISE, S., A. LAGACE, C. GIRARD, AND P. BELAND. 1993. Intramuscular *Sarcocystis* in two beluga whales and an Atlantic white-sided dolphin from the St. Lawrence Estuary, Quebec, Canada. *Journal of Veterinary Diagnostic Investigation* 5: 296–300.
- DUBEY, J. P., C. A. SPEER, AND R. FAYER. 1989. *Sarcocystosis of animals and man*. CRC Press, Inc., Boca Raton, Florida, pp. 2–104.
- , W. J. A. SAVILLE, D. S. LINDSAY, R. W. STICH, J. F. STANEK, C. A. SPEER, B. M. ROSENTHAL, C. J. NJOKU, O. C. H. KWOK, S. K. SHEN, AND S. M. REED. 2000. Completion of the life cycle of *Sarcocystis neurona*. *Journal of Parasitology* 86: 1276–1280.
- , D. S. LINDSAY, D. FRITZ, AND C. SPEER. 2001. Structure of *Sarcocystis neurona* sarcocysts. *Journal of Parasitology* 87: In press.
- LAPOINTE, J. M., P. J. DUIGNAN, A. E. MARSH, F. M. GULLAND, C. BARR, D. K. NAYDEN, D. P. KING, C. A. FARMAN, K. A. BUREK HUNTINGDON, AND L. J. LOWENSTEIN. 1998. Meningoencephalitis due to a *Sarcocystis neurona*-like protozoan in Pacific harbor seals (*Phoca vitulina richardsi*). *Journal of Parasitology* 84: 1184–1189.
- LINDSAY, D. S., N. J. THOMAS, AND J. P. DUBEY. 2000. Biological characterization of *Sarcocystis neurona* isolated from a southern sea otter (*Enhydra lutris nereis*). *International Journal for Parasitology* 30: 617–624.
- MEHLHORN, H., W. J. HARTLEY, AND A. O. HEYDORN. 1976. A comparative ultrastructural study of the cyst wall of 13 *Sarcocystis* species. *Protistologica* 12: 451–467.
- MUNDAY, B. L., R. W. MASON, W. J. HARTLEY, P. J. A. PRESIDENTE, AND D. OBENDORF. 1978. *Sarcocystis* and related organisms in Australian wildlife: I. Survey findings in mammals. *Journal of Wildlife Diseases* 14: 417–433.
- OWEN, C. C., AND R. A. DADULAS. 1967. Sarcosporidiosis in sperm whale. *Australia Journal of Science* 31: 46–47.
- ROSONOKE, B. J., S. R. BROWN, S. J. TORNQUIST, S. P. SNYDER, M. M. GARNER, AND L. L. BLYTHE. 1999. Encephalomyelitis associated with a *Sarcocystis neurona*-like organism in a sea otter. *Journal of the American Veterinary Medical Association* 215: 1839–1842.

Received for publication 23 September 2000.